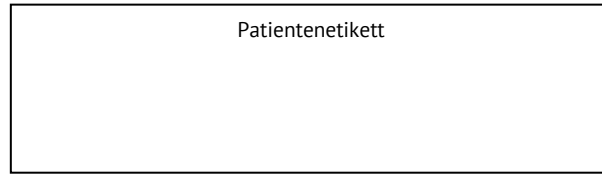
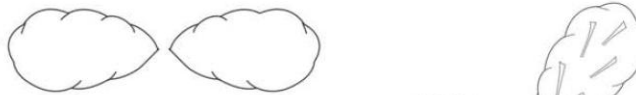




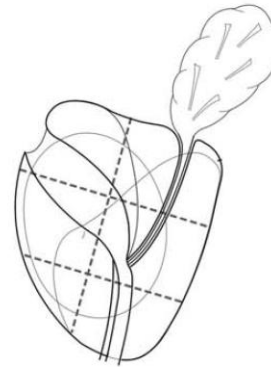
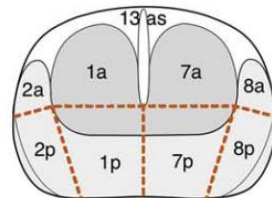
Lokalisationsschema zur MRT Untersuchung der Prostata



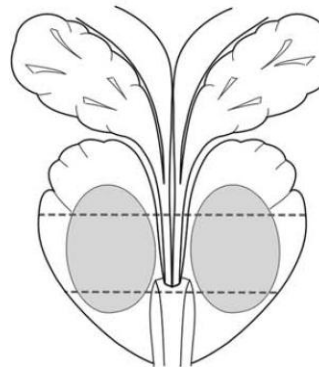
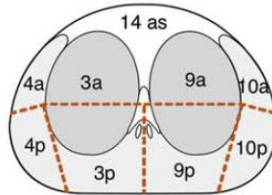
Samenbläschen



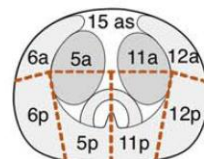
Basis



Mitte



Apex



a = anterior
p = posterior
as = anteriores Stroma